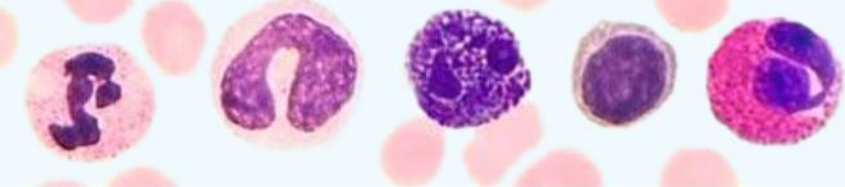
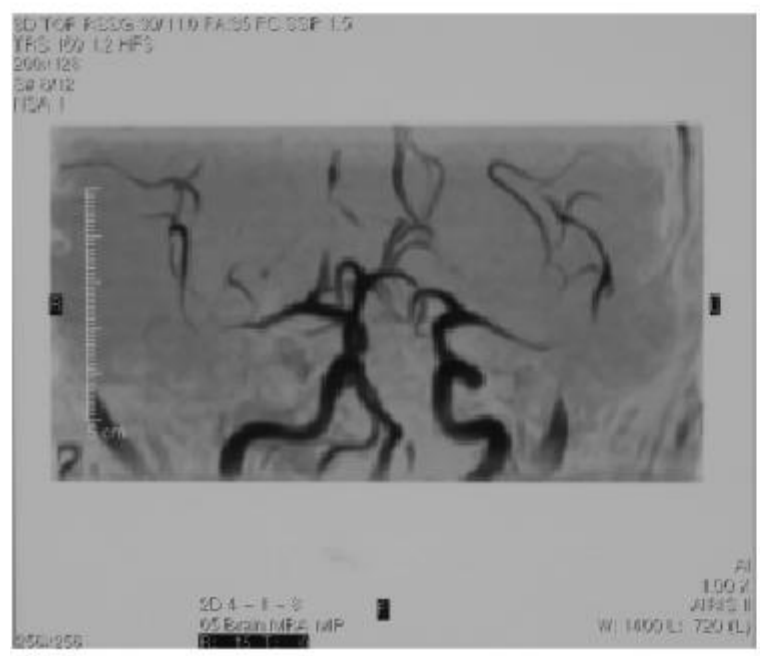

Cerebral Arteriosclerosis (69 year old, male)

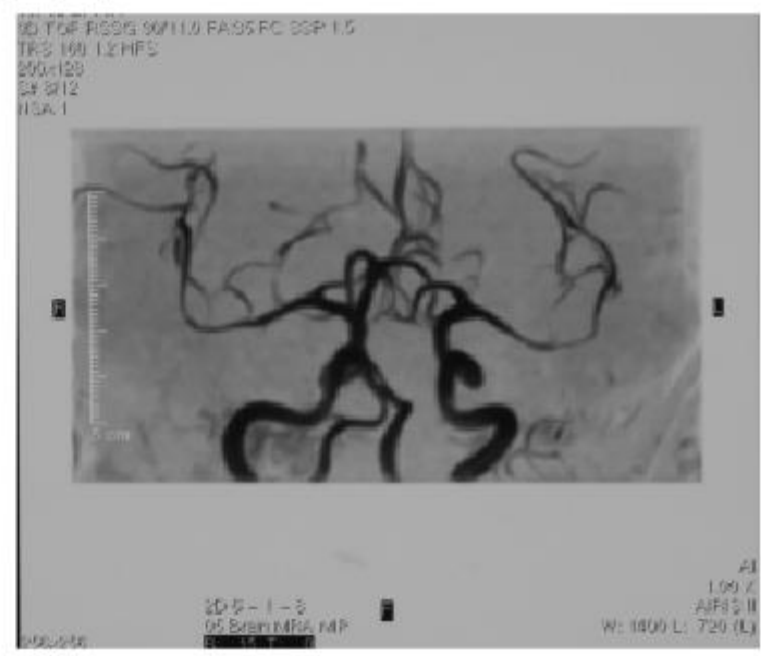

Cerebral Arteriosclerosis (69 year old, male)

MR Angiography



The 26th shooting February 19, 2007



The 19th shooting September 19, 2007

Electron reduction of blood flow improvement after treatment (7 months), arterial brain