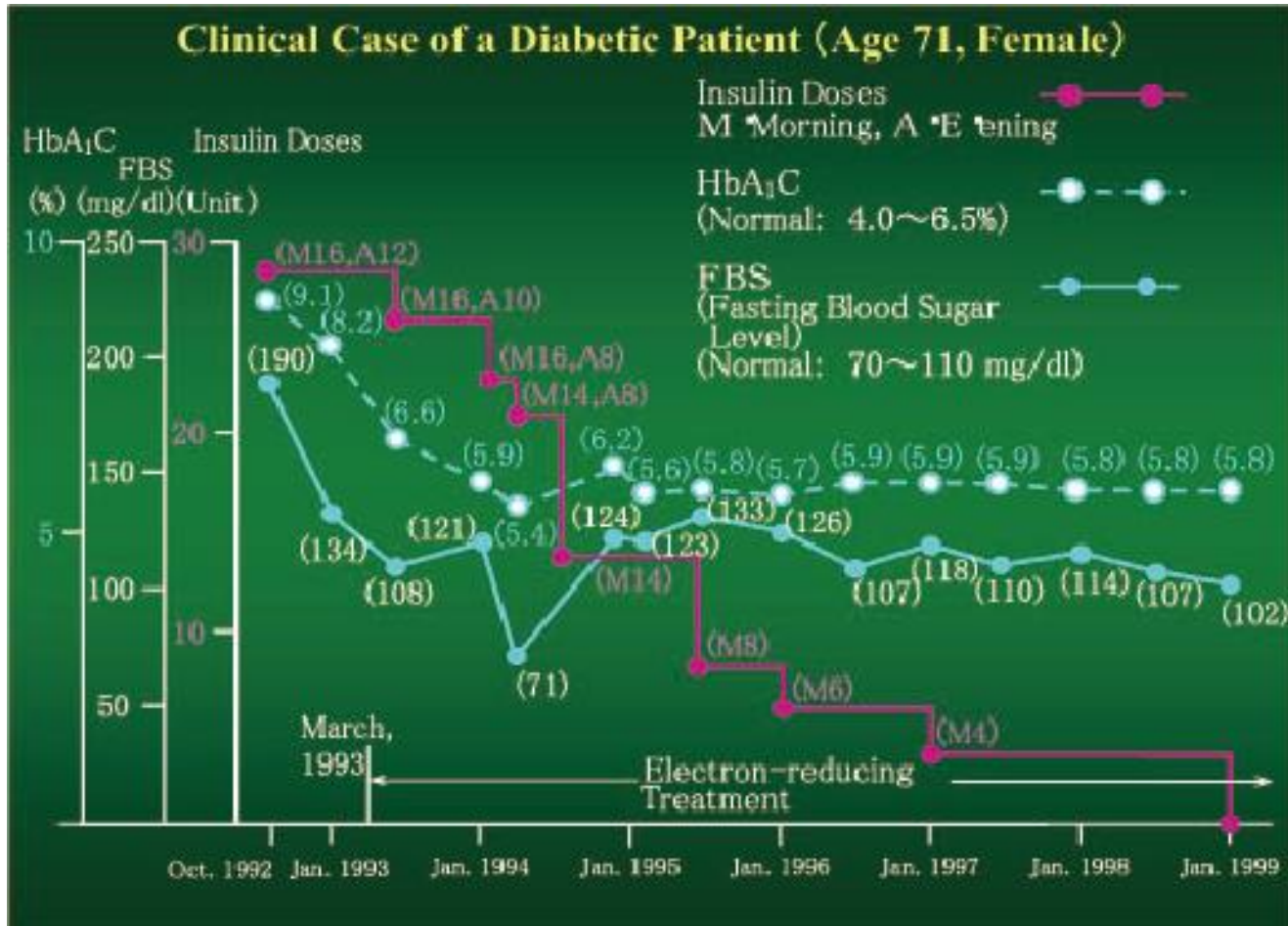


# Diabetes Mellitus

## Diabetic (Case 1)

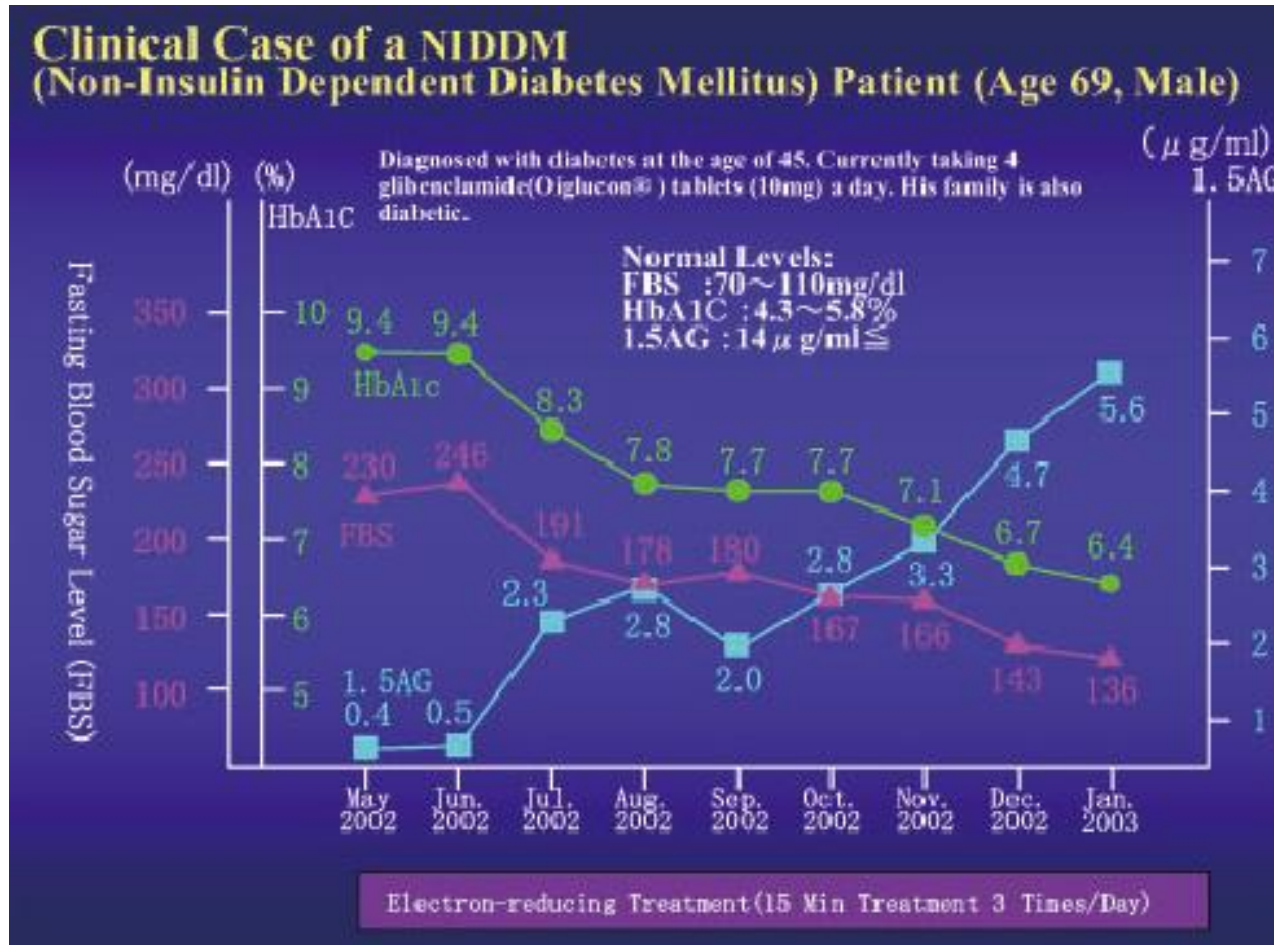


## **Clinical case of a diabetic patient, age 71, female**

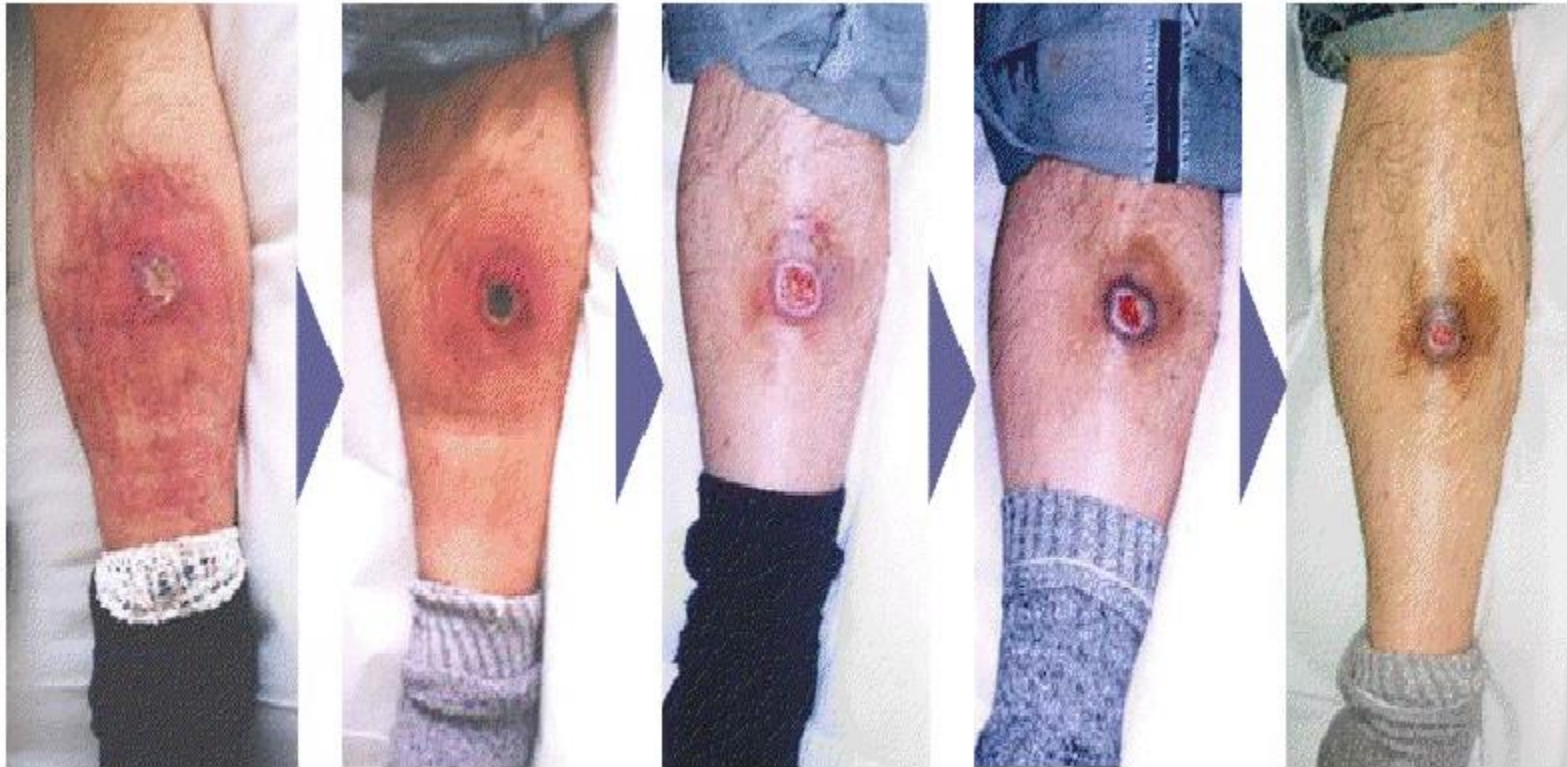Patient suffers from type II diabetes, vision impairment and leg necrosis. Electron-reducing treatment started in 1992.

In 1992, 28 units of insulin, 16 units in the morning and 12 units in the evening was administered. Despite such insulin doses, patient's fasting glucose level was 190mg/dl and HbA1C was 9.1%. After electron-reducing treatment, no insulin units was required as of January 1999 as patient's fasting glucose levels were back to normal at 102mg/dl without insulin dose.

## Diabetic (Case 2)



**Diabetic Ulcer** (Case 3 : 40 year old, male)



治療前

4日後

9日後

22日後

87日後

**Diabetic** (Case 4)

Changes on Gangrene, 90 years, Female

